

A case of two siblings with Morquio syndrome

Kankanarachchi I¹, Amarasena S¹


¹Faculty of Medicine, University of Ruhuna, Sri Lanka

Abstract

Morquio syndrome (Type IV mucopolysaccharidosis) is an autosomal recessive condition with a prevalence of 1:40000 to 1:200000.¹ The deficiencies of N-acetyl-galactosamine-6-sulfatase and beta-galactosidase leads to accumulation of glycosaminoglycan resulting Morquio syndrome type A and B respectively. Here, we report a case of two siblings with Morquio syndrome. Parents brought two male siblings aged 5 years and 30 months due to abnormal physical appearance. They were born to non-consanguineous healthy parents who had uneventful antenatal periods. Parents were worried about short stature and abnormal chest shape. On examination, both of them had similar physical characteristics such as a coarse face, short stature, pectus carinatum, scoliosis, short neck, coxa vulga, and multiple bony deformities. They had normal basic biochemistry, haematological indices, and bone profile. Thoracolumbar spine and pelvis X rays showed platyspondyly with anterior beaking and flaring of iliac wings. Ophthalmology assessment of both siblings revealed amblyopia. Both siblings had elevated urine glycosaminoglycans. Qualitative urine analysis showed moderate excretion of chondroitin sulphate and mildly elevated Heparan sulphate, which favoured MPS type IV. Lysosomal enzyme assay performed on elder sibling showed a low level of beta-galactosidase-6-Sulphate-Sulphatase and normal level of beta-galactosidase, and the diagnosis was confirmed as MPS type IV-A. Since no curative therapy was available yet, parents were explained about the disease condition, and follow-up was arranged with a multidisciplinary approach. Unfortunately, there is a significant amount of financial constraint in diagnosing and managing Morquio syndrome. Developing countries such as Sri Lanka cannot afford enzyme replacement therapy, and HSCT is not developed for children with inborn errors of metabolism. However, it is essential to have surveillance for anticipated complications of the condition with a multidisciplinary team approach until a cheaper disease-modifying agent is available.

Key Words: primary aldosteronism, adrenal venous sampling, unilateral catheterization

Correspondence email: imalke462@gmail.com

 <https://orcid.org/0000-0002-9351-2966>



This is an open-access article distributed under the terms of the Creative Commons Attribution License, which permits unrestricted use, distribution, and reproduction in any medium, provided the original author and source are credited (CC BY 4.0)

Introduction

Morquio syndrome (Type IV mucopolysaccharidosis) is an autosomal recessive condition with a prevalence of 1:40000 to 1:200000.¹ The deficiencies of N-acetyl-galactosamine-6-sulfatase and beta-galactosidase leads to accumulation of glycosaminoglycan resulting in Morquio syndrome type A and

B respectively (1). Here, we report a case of two siblings with Morquio syndrome.

Case Report

Two siblings, 5 years old boy (Case 1, figure 1) and 2 years and 6-month old boy (Case 2, figure 2) were brought by parents due to abnormal physical ap-

pearance. They were born to non-consanguineous healthy parents who had uneventful antenatal periods. Parents were worried about short stature and abnormal chest shape. On examination, both of them had similar physical characteristics such as a

coarse face, short stature, pectus carinatum, scoliosis, short neck, coxa vulga, and multiple bony deformities. Both of them had normal intellectual development.

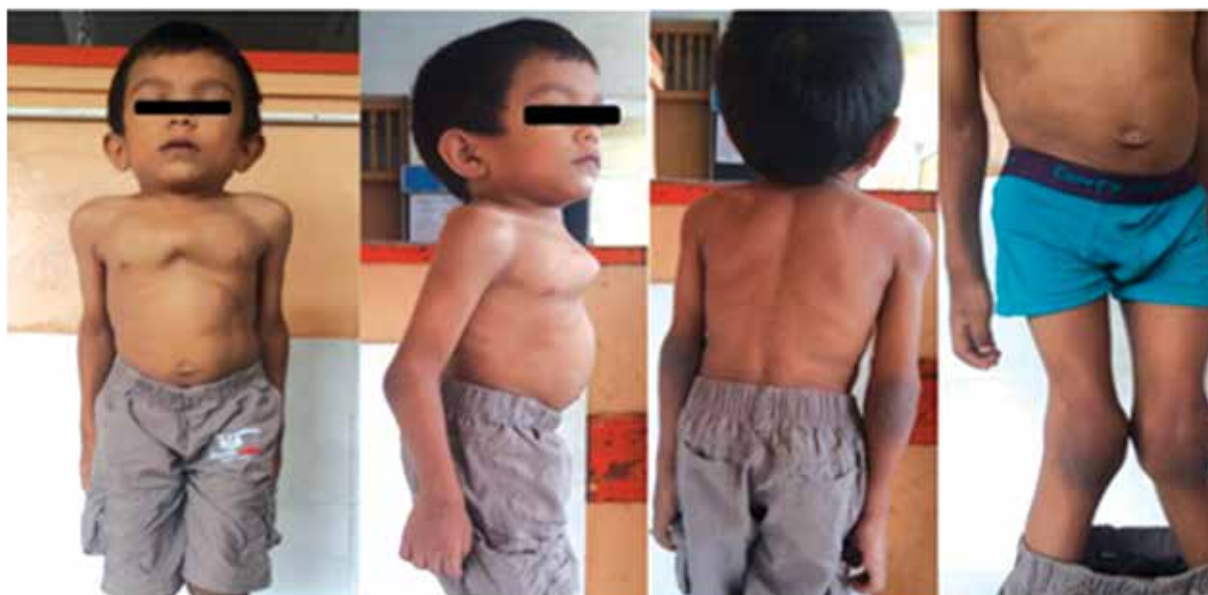

Figure 1 Five-year-old boy with Morquio syndrome

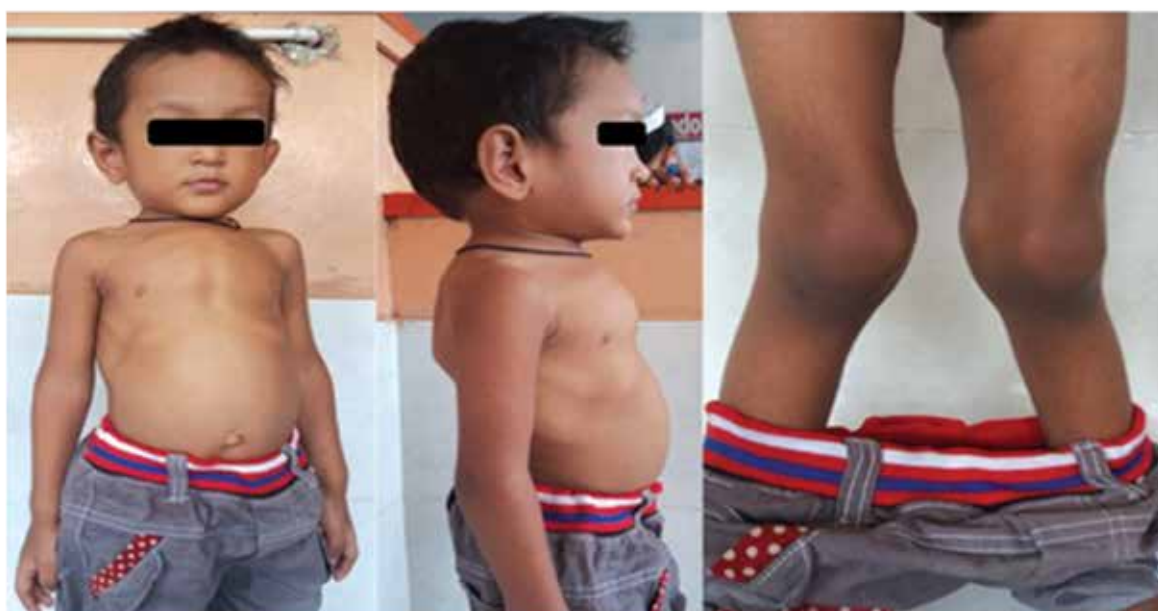

Figure 2 Three-year-old boy with Morquio syndrome

Both siblings had normal basic biochemistry, hematological indices, and bone profile. Thoracolumbar spine and pelvis X-rays of

both siblings showed flat ended vertebral bodies (platyspondyly) with anterior beaking and flaring of iliac wings (Figure 3).

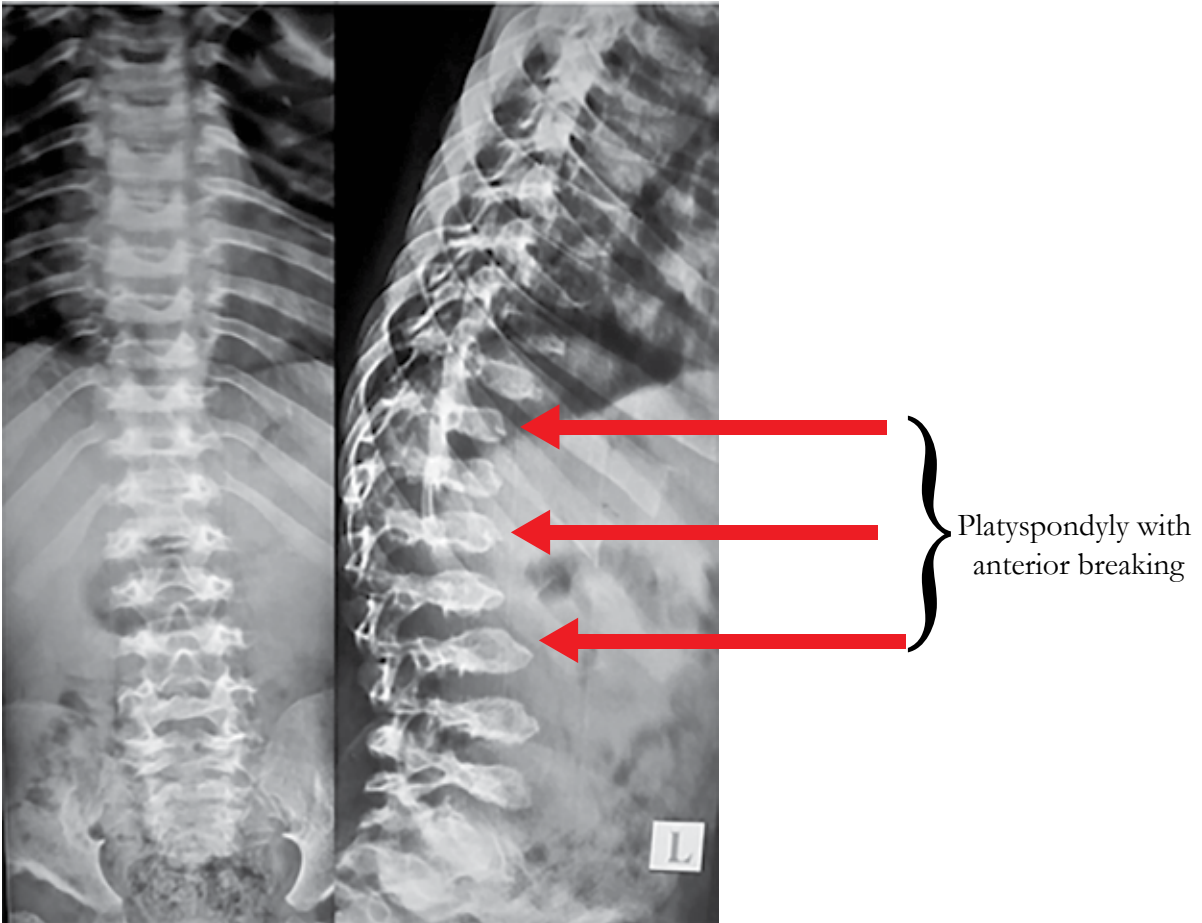


Figure 3 X-ray thoracolumbar spine

Their hand X-ray revealed broad metacarpals, pointed proximal metacarpals of second and fifth carpals, irregular carpal bones, and fingers (Figure 4).

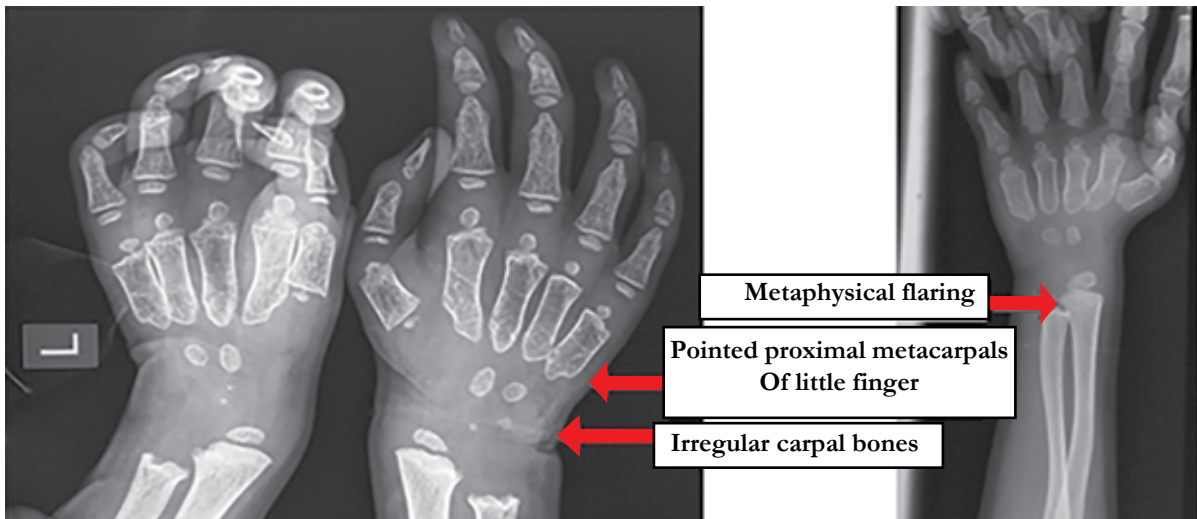


Figure 4 Hand X rays showing carpal and metacarpal bone changes

Due to the clinical suspicion of Mucopolysaccharidosis (MPS), the siblings underwent testing for urine for Glucosamine glycan (GAG) and they had elevated urine for GAG. Qualitative urine analysis showed moderate excretion of chondroitin sulfate and mildly elevated Heparan sulfate which was more in favor of MPS type IV. The lysosomal enzyme assay was performed in the elder brother's blood and showed a low level of beta-galactosidase-6-Sulphate-Sulphatase, 6.2 nmol/hrs/mg protein (14-32). and normal level of beta-galactosidase, 210.1 nmols/hrs/mg protein (79.6-480.0). Based on the findings of enzyme assay the diagnosis of Morquio A (MPS type IVA) was made on an elder sibling. The lysosomal enzyme assay was not done on the younger brother at the time of publication.

Ophthalmology assessments of both siblings revealed amblyopia and they were prescribed on spectacles. The hearing assessments did not reveal any deficiency. There was no abnormality found in the 2D echocardiographs. Since no curative therapy was available yet, parents were explained about the disease condition and follow-up was arranged with a multidisciplinary approach.

Discussion

Morquio syndrome A is secondary to the accumulation of Keratan sulfate and chondroitin Sulphate in the Extracellular matrix and cartilages due to a defect in the metabolism of glycosaminoglycan (2). The deficient enzyme in MS is N-acetyl-galactosamine-6-sulfatase and the genetic mutation occurs on chromosome 16q24.3 (2). Preservation of intelligence and short trunk dwarfisms are the two distinctive features of MS compared to other MPS. MPS IV-A is more severe compared to MPS-IVB with an average adult height of around 125cm and 150 cm respectively (3).

Skeletal manifestations of MPS IV-A are coxa vulgar, short stature, kyphosis, pectus carinatum, and short neck. Instability of the odontoid process is very common and can lead to paraplegia in later life. Corneal clouding, glaucoma obstructive airway disease, dental anomalies, and valvular heart lesions are common extra skeletal malformations of the disease (3). Skeletal abnormalities manifest earlier than

other organ involvement and that would have been the reason for these siblings to not have significant extraskeletal manifestations yet.

Characteristic axial radiological findings of MPS IV-A include Platyspondyly, anterior beaking, atlanto axial subluxation, and goblet-shaped iliac wings. Metaphyseal flaring in long bones, irregular carpal bones, pointed metacarpals of the 5th finger, and short and wide tubular bones are some of the peripheral radiological features in MPS IV-A (3). Most of these radiological features were there in these two patients.

The initial clue for the diagnosis of MPS IV-A is elevated urine GAG and elevated KS in blood. Confirmation of the diagnosis needs a lysosomal enzyme assay. Genotyping is optional and is mainly used in genetic counseling (4). MPS IV -A can be treated with enzyme replacement therapy (ERT), Elosulfase alfa. However, the annual cost is around \$380,000 per patient (4). Hematopoietic stem cell transplant has also been an established treatment modality (5). Substrate reduction therapy using flavonoid compounds, anti-inflammatory medications such as Infliximab and Gene therapy are still under the research level. All patients should be managed with a multidisciplinary approach involving, orthopedic, cardiology, ophthalmology, respiratory, maxillofacial, and otolaryngology teams. In the absence of newer treatment modalities, these two patients were given a multidisciplinary follow-up plan.

Conclusions

There is a significant amount of financial constraints in diagnosing and managing Morquio syndrome. Developing countries such as Sri Lanka cannot afford ERT and HSCT is not developed for children with inborn errors of metabolism. However, it is important to have surveillance for anticipated complications of the condition with a multidisciplinary team approach until a cheaper disease-modifying agent is available.

Acknowledgment

The authors would like to acknowledge Dr. Eresha Jasinghe, and the Department of Radiology,

TH Karapitiya to facilitate diagnostic testing of the child.

References

1. Eggli KD, Dorst JP. The mucopolysaccharidoses and related conditions. *In Seminars in roentgenology* 1986 Oct 1; **21**(4); 275-294. WB Saunders. doi.org/10.1016/0037-198X(86)90039-8
2. Kliegman, Stanton, St Geme Schor, Nelson Textbook of Paediatrics. 20th Ed. Philadelphia, PA: Elsevier, 2016. Chapter 88: Mucopolysaccharidoses; p. 742
3. Montaña AM, Tomatsu S, Gottesman GS, Smith M, Orii T. International Morquio A Registry: clinical manifestation and natural course of Morquio A disease. *Journal of Inherited Metabolic Disease: Official Journal of the Society for the Study of Inborn Errors of Metabolism*. 2007Apr;**30**(2):165-74. doi.org/10.1007/s10545-007-0529-7
4. Tomatsu S, Yasuda E, Patel P, Ruhnke K, Shimada T, Mackenzie WG, Mason R, Thacker MM, Theroux M, Montaña AM, Alméciga-Díaz CJ. Morquio A syndrome: diagnosis and current and future therapies. *Pediatric endocrinology reviews: PER*. 2014 Sep;**12**(0 1):141.
5. Yabe H, Tanaka A, Chinen Y, Kato S, Sawamoto K, Yasuda E, Shintaku H, Suzuki Y, Orii T, Tomatsu S. Hematopoietic stem cell transplantation for Morquio A syndrome. *Molecular genetics and metabolism*. 2016 Feb1;**117**(2):84-94. doi.org/10.1016/j.ymgme.2015.09.011