

Asparagus falcatus L. (Asparagaceae) leaf extracts attenuate doxorubicin-induced renal toxicity via antioxidant, anti-inflammatory, and anti-apoptotic pathways

Sachintha S. Amarasiri, Anoja P. Attanayake, Lakmini K. B. Mudduwa & Kamani A. P. W. Jayatilaka

To cite this article: Sachintha S. Amarasiri, Anoja P. Attanayake, Lakmini K. B. Mudduwa & Kamani A. P. W. Jayatilaka (2022): *Asparagus falcatus* L. (Asparagaceae) leaf extracts attenuate doxorubicin-induced renal toxicity via antioxidant, anti-inflammatory, and anti-apoptotic pathways, Drug and Chemical Toxicology, DOI: [10.1080/01480545.2022.2080218](https://doi.org/10.1080/01480545.2022.2080218)

To link to this article: <https://doi.org/10.1080/01480545.2022.2080218>



Published online: 30 May 2022.



Submit your article to this journal [↗](#)

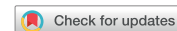

View related articles [↗](#)



View Crossmark data [↗](#)

RESEARCH ARTICLE



Asparagus falcatus L. (Asparagaceae) leaf extracts attenuate doxorubicin-induced renal toxicity via antioxidant, anti-inflammatory, and anti-apoptotic pathways

Sachintha S. Amarasiri^a, Anoja P. Attanayake^b, Lakmini K. B. Mudduwa^c and Kamani A. P. W. Jayatilaka^b

^aDepartment of Medical Laboratory Science, Faculty of Allied Health Sciences, University of Ruhuna, Galle, Sri Lanka; ^bDepartment of Biochemistry, Faculty of Medicine, University of Ruhuna, Galle, Sri Lanka; ^cDepartment of Pathology, Faculty of Medicine, University of Ruhuna, Galle, Sri Lanka

ABSTRACT

The search for therapeutic agents that improve kidney function against doxorubicin-induced renal toxicity is important. Herein, the potential nephroprotective activity by *Asparagus falcatus* L. (AF, Asparagaceae) leaf extracts against doxorubicin-induced renal toxicity (5 mg/kg, ip) in Wistar rats ($n = 6$ /group) after oral administration of hexane (55 mg/kg), ethyl acetate (35 mg/kg), butanol (75 mg/kg), and aqueous (200 mg/kg) extracts of AF for 28 consecutive days was investigated. It was noticed that the treatment with the selected extracts of AF significantly attenuated doxorubicin-induced elevations of serum creatinine, urea nitrogen, β_2 -microglobulin, cystatin C, and proteinuria in experimental rats. The histology showed attenuation of the features of acute tubular injury. Treatment regimens significantly reversed the doxorubicin-induced reduction in total antioxidant status, glutathione peroxidase, and glutathione reductase activity in renal tissue homogenates. A suppression in lipid peroxidation was noted with hexane, ethyl acetate, and butanol extracts of AF. Moreover, a reduction in the concentration of the pro-inflammatory mediator TNF- α ($p < 0.05$), and immunohistochemical expression of COX-2 were observed. The immunohistochemical expression of pro-apoptotic Bax protein was decreased and the anti-apoptotic BCL-2 was increased in renal tissues following the treatments. In conclusion, it was revealed that, hexane, ethyl acetate, butanol, and aqueous extracts of AF attenuate doxorubicin-induced renal toxicity in Wistar rats through antioxidant, anti-inflammatory, and anti-apoptotic pathways. The plant, AF could be recommended as a promising therapeutic agent to minimize renal toxicity induced by doxorubicin in cancer patients, however, subsequent clinical trials are warranted.

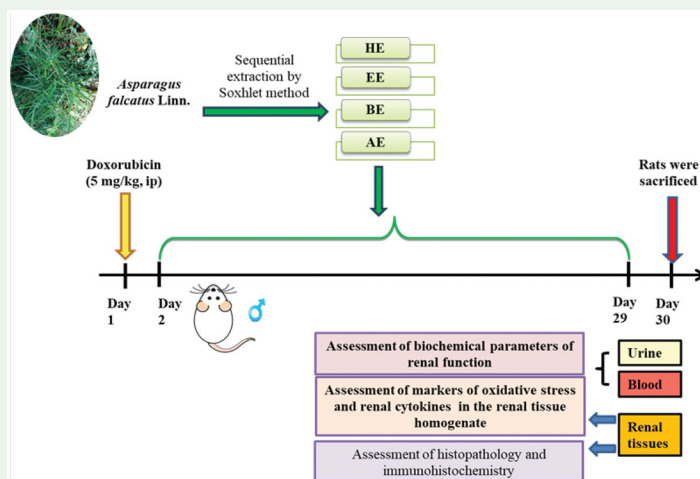
ARTICLE HISTORY

Received 31 January 2022
Revised 16 May 2022
Accepted 16 May 2022

KEYWORDS

Anti-apoptotic effects; anti-inflammatory effects; antioxidant potential; *Asparagus falcatus*; doxorubicin; renal toxicity

GRAPHICAL ABSTRACT



Introduction

Traditional oncologic drugs demonstrate on-target toxicity, affecting cancer cells as well as healthy tissues in contact, with the same pharmacological effects leading to multi-organ toxicity (Negrette-Guzmán 2019). Hence, the

administration of anticancer drugs has become a leading cause of drug-induced renal toxicity in cancer patients. In this context, the use of the anticancer drug, doxorubicin, has been reduced to a certain degree due to its dose-dependent renal toxicity effects (El-Sheikh *et al.* 2012,

Benzer *et al.* 2018, Heravi *et al.* 2018). The potential toxicity effects of doxorubicin have led researchers to explore alternative therapeutic strategies for preventing disease progression and improving kidney function against doxorubicin-induced renal toxicity.

Renal toxicity provoked by doxorubicin is well explained via the mechanisms of oxidative changes, apoptosis, inflammation, etc. A substantial increase in the generation of reactive oxygen species and biologically reactive intermediates tends to result in potential renal damage by subsequent unrestrained lipid peroxidation and precipitous decline in the robust enzymatic antioxidant system in doxorubicin therapy (Lahoti *et al.* 2012). The previous research revealed that the activation of apoptotic pathways, mainly regulated via a series of regulatory proteins of the B-cell lymphoma-2 family, has a critical role in propagating doxorubicin-induced cellular toxicity (Lahoti *et al.* 2012, Ibrahim *et al.* 2020). Furthermore, doxorubicin triggers the production and release of various pro-inflammatory cytokines from leukocytes and renal tubular cells, stimulating inflammatory pathways leading to renal toxicity (Yu *et al.* 2017, Ibrahim *et al.* 2020). Hence, potential approaches for attenuating oxidative stress, apoptosis, and inflammation might produce promising therapeutic strategies against doxorubicin-induced renal toxicity.

Asparagus falcatus L. (AF) of the Asparagaceae family has been used as a dietary supplement as well as conventional medicine in Sri Lanka since ancient times. The clinical application of the plant for renal diseases, particularly, dysuria and hematuria, has been documented in the Ayurvedic texts (Jayaweera 1982, Anon 1985). However, there is a scarcity of evidence on the scientific scrutinization of AF for potential bioactivities. Some phytoconstituents have been isolated from AF such as lupenyl palmitate, 1-hexacosanol, furanosesquaterpene diolide, aspfalcolide, and eupalitin. However, potential bioactivities have been reported only for aspfalcolide and eupalitin as antiangiogenic and anticancer properties, respectively (Ghalib *et al.* 2012, Ghalib *et al.* 2013, Ali and Sultana 2016). In fact, the authors reported the potential nephroprotective effects of standardized aqueous leaf extract of AF in an animal model of renal toxicity, for the first time (Amarasiri *et al.* 2020a). However, the primary outcome of the aforementioned study was the evaluation of the potential efficacy of the plant in nephroprotection through the evaluation of some selected markers of renal toxicity and renal pathology. Apparently, the potential nephroprotective mechanisms of administration of AF upon long-term exposure have not been elucidated to date. A proper elucidation of the protective mechanisms of a therapeutic agent is a primary requirement in the process of drug discovery (Sharma and Gupta 2015). Therefore, the present study was carried out to investigate nephroprotective mechanisms after oral administration of the selected AF extracts for an extended period, using a renal toxicity model induced by doxorubicin in Wistar albino rats observed under biochemical, histopathological, and immunohistochemical assessments.

Materials and methods

Plant extraction

Leaves of AF were collected from the Southern region of Sri Lanka (6°04'05" N, 80°13'35" E), in May 2018. The plant was authenticated at the Sri Lankan National Herbarium and the voucher specimen was deposited in the mini-herbarium under No. PG/2016/55/02 at the Department of Biochemistry, Faculty of Medicine, University of Ruhuna, Sri Lanka. The oven-dried (40 °C) powdered leaf material of AF was sequentially extracted with hexane, ethyl acetate, butanol, and water by the sequential soxhlet extraction method (Gopalsatheeskumar 2018, Amarasiri *et al.* 2020b). Organic solvents were removed by rotary evaporation (Buchi, B-480, UK) and dried at 40 °C in a vacuum to achieve semi-solid masses. The aqueous extracts were lyophilized. The percentage yield for the hexane, ethyl acetate, butanol, and aqueous extracts based on the initial weight of the dried plant material were 4.51%, 2.80%, 6.11%, and 16.88% respectively.

Experimental animals

The animal study protocol was carried out within the guidelines of the Medical Faculty, Ethics Review Committee (ERC), University of Ruhuna (ERC – 14.12.2015:3.1). Male Wistar albino rats of age 10–12 weeks (175 ± 25 g) were used for the experiments.

Experimental design

Renal toxicity was induced with a single intraperitoneal dose of doxorubicin (DXR, Doxutec: United Biotech, India) at 5 mg/kg, in a volume of 0.2 mL/150 g of fasted (8 h) healthy male Wistar albino rats. The dose of DXR was selected based on the preliminary experiments and data from the literature (Heravi *et al.* 2018). The experimental animals were grouped randomly into seven groups (six rats per group). Consequently, the doses selected for hexane, ethyl acetate, butanol, and aqueous extracts of AF were 55 mg/kg, 35 mg/kg, 75 mg/kg, and 200 mg/kg respectively (equivalent human therapeutic doses at respective extracts). The above doses were calculated based on the human therapeutic dose and the extraction yield of plant extracts (Dhawan and Srimal 1997). The treatment regimens were started 24 hours after the induction of renal toxicity and continued for 28 consecutive days as a single oral dose. The treatment regimens were as follows; experimental rats of groups I and II served as normal and the DXR controls respectively, received distilled water. DXR induced renal toxic rats in groups III–VI were treated with hexane (55 mg/kg), ethyl acetate (35 mg/kg), butanol (75 mg/kg), and aqueous (200 mg/kg) extracts of AF respectively. Group VII served as the positive control; DXR-induced renal toxic rats were administered with the standard drug, fasinopril sodium (Sigma-Aldrich: St. Louis, MO, USA; 0.09 mg/kg).

The rat body weights, food consumption, and water intake were measured daily and averaged weekly. The animals were raised in diuresis cages immediately after the last treatment

and their urine samples were collected in 24 h. On the 29th day, the fasting animals were sacrificed by inhalation of an overdose of CO₂ (EUTH 2A CO₂ Euthanasia chamber, Orchid Scientific, India) and their blood samples were drawn by cardiac puncture for biochemical assessment.

The kidneys of the sacrificed animals were removed and half of each kidney was dipped in ice-cold phosphate-buffered saline (0.1 M PBS, pH = 7.4) for the preparation of kidney homogenates to be used in the biochemical assessment of antioxidant and anti-inflammatory markers. The remaining halves of the excised kidneys were preserved in 10% formaldehyde for histopathological and immunohistochemical studies.

Assessment of biochemical parameters of renal function

The serum concentrations of creatinine, urea nitrogen, and total protein in urine were estimated, using spectrophotometric assay kits (Biorex diagnostics, UK and Stanbio Laboratory, USA) following the previously reported methods (Bartels *et al.* 1972, Sampson *et al.* 1980, Watanabe *et al.* 1986). The serum concentrations of β_2 -microglobulin and cystatin C were estimated using enzyme-linked immunosorbent assay kits (DRG Instruments GmbH, Germany and Elabscience Biotechnology Inc, USA).

Evaluation of markers of oxidative stress in renal tissue homogenate

Quantification of total antioxidant status, estimation of glutathione reductase activity, glutathione peroxidase activity, and malonaldehyde concentration, as a product of lipid peroxidation were carried out, following the standard protocols (Paglia and Valentine 1967, Carlberg and Mannervik 1985, Halliwell and Gutteridge 2000, Muriel *et al.* 2001).

Evaluation of renal cytokines in renal tissue homogenate

The concentration of renal cytokines including tumor necrosis factor α (TNF- α) and interleukin 1 β (IL-1 β) were measured in renal tissue homogenates, using enzyme-linked immunosorbent assay methods (Elabscience Biotechnology Inc, USA).

Immunohistochemistry of COX-2, Bax, and BCL-2

The kidney tissue sections were deparaffinized and rehydrated with xylene and a series of graded ethanol. After antigen retrieval and elimination of endogenous peroxidase activity, they were incubated with mouse monoclonal anti-cyclooxygenase-2 antibody; anti-COX-2, (Dako, Denmark, 1:100 dilution), mouse monoclonal antibody against B-cell lymphoma gene product 2; BCL-2 gene product, (Dako, Denmark, 1: 25 dilution), and mouse polyclonal antibody associated with X protein; anti-Bax (Abcam, UK, 1:100 dilution). The slides were incubated with HRP- conjugated secondary antibody, and diaminobenzidine (DAB) substrate

respectively and counterstained with hematoxylin for examination under the light microscope (Olympus CX 21, Japan).

The intensity of staining in renal tissues immunostained with COX-2, Bax, and BCL-2 was graded, using a semi-quantitative intensity scale from 0 to 3. A group of hundred consecutive tubular epithelial cells in five random high-power fields ($\times 400$) per rat were classified as 0: no staining, 1: mild staining, 2: moderate staining, and 3: dense staining in the renal cortex. A positive stain intensity presented as an average percentage of the total number of tubular epithelial cells was counted in each experimental group. Furthermore, the apoptotic index (ratio of percentage number of cells stained with Bax and percentage number of cells stained with BCL-2; Bax/BCL-2 ratio) of the different groups of experimental rats was calculated based on the findings of the semi-quantitative analysis of immunostained renal tissues (Ding *et al.* 2011).

Semi-quantitative assessment of histopathology in renal tissue

Further, the kidney sections stained with hematoxylin and eosin (H and E) were used for light microscopic examination. There, twenty high power fields ($\times 400$) were examined in the renal sections of each experimental rat in accordance with a modified version of the semi-morphometric scores reported previously (Amarasiri *et al.* 2020a) as mentioned in Table 1.

Statistical analysis

The data were analyzed using the statistical package for social sciences (SPSS) version 22.0 (IBM SPSS Statistics 22, New York, USA). The quantitative data were expressed as mean \pm SEM. The statistical analysis of biochemical data of *in vivo* study and weekly data of body weight and food consumption was performed by one-way ANOVA and two-way ANOVA respectively, followed by Tukey's post-hoc test. The semi-morphometric histopathological scores and the semi-quantitative immunostaining analysis were evaluated, using the Kruskal–Wallis, Dunn's post-hoc test. The differences between the means were considered to be statistically significant when $p < 0.05$. Pearson's correlation between the selected parameters was also assessed and statistical significance was set at $p < 0.05$.

Table 1. Semi morphometric assessment of histological changes.

Feature	Description	Score
Tubular vacuolization	Absence of the feature	0
Loss of tubular brush border	Presence <25% of the field	1
Nuclear pyknosis	Presence <50% of the field	2
Glomerular congestion	Presence <75% of the field	3
	Presence >75% of the field	4
Intertubular hemorrhage	Absence of the feature	0
	Presence of the feature	1
Presence of tubular casts	Absence of the feature	0
	Presence of 1 cast	1
	Presence of >1 cast	2
Inflammatory cell infiltration	Absence of the feature	0
	Presence of the feature	1

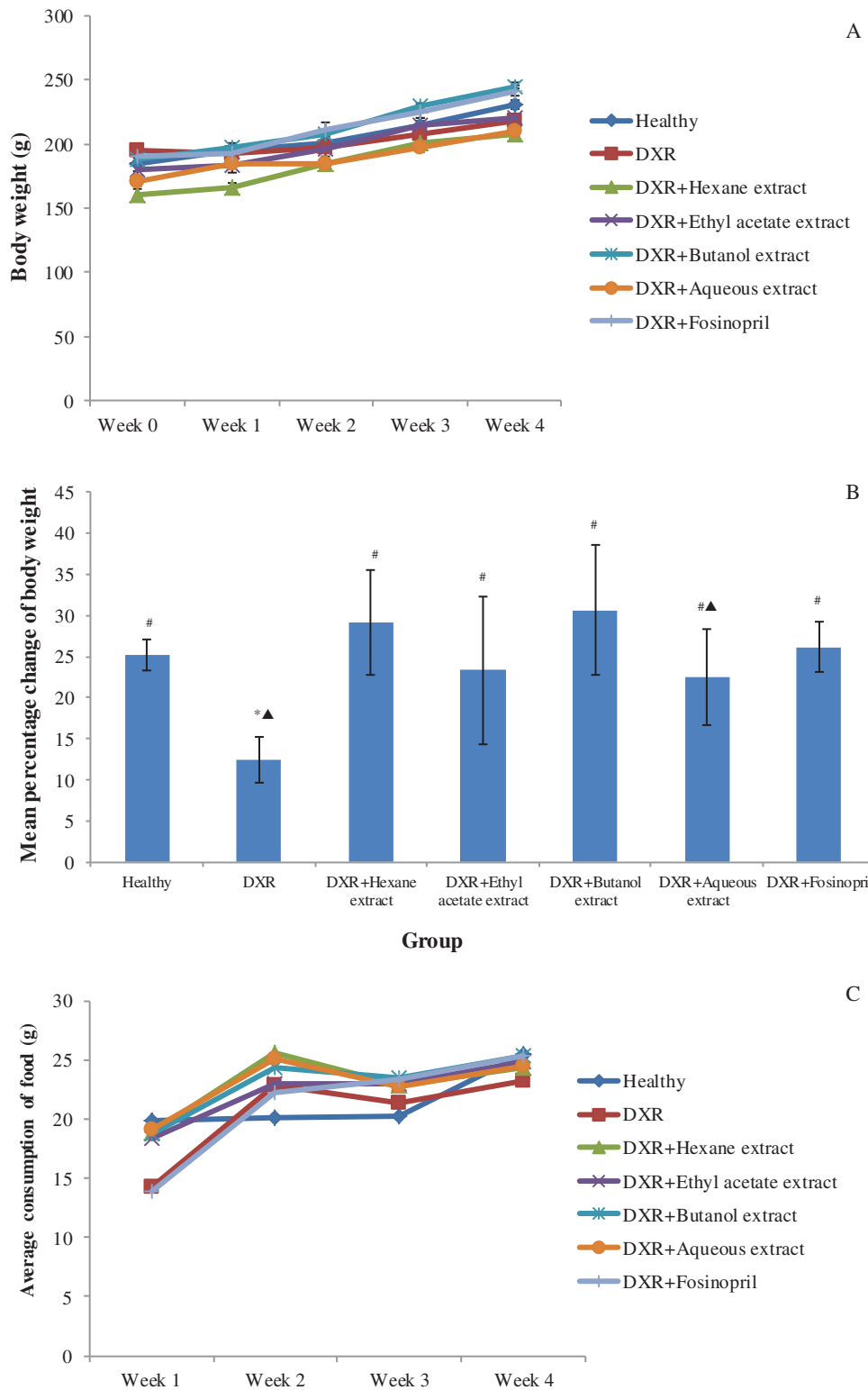


Figure 1. Effect of *Asparagus falcatus* on evaluation of body weight throughout the study period of four weeks (A), body weight gain (B), average consumption of food (C) and average intake of water (D) in doxorubicin-induced renal toxicity in Wistar albino rats. DXR: doxorubicin. The treatment groups consisted of experimental rats administered with hexane (55 mg/kg), ethyl acetate (35 mg/kg), butanol (75 mg/kg), and aqueous (200 mg/kg) extracts of *A. falcatus* and the standard drug, fosinopril (0.09 mg/kg). Each data point is expressed in mean \pm SEM ($n = 6$). * $p < 0.05$ vs. normal healthy rats, # $p < 0.05$ vs. doxorubicin control rats, ▲ $p < 0.05$ vs. positive control rats. DXR: doxorubicin.

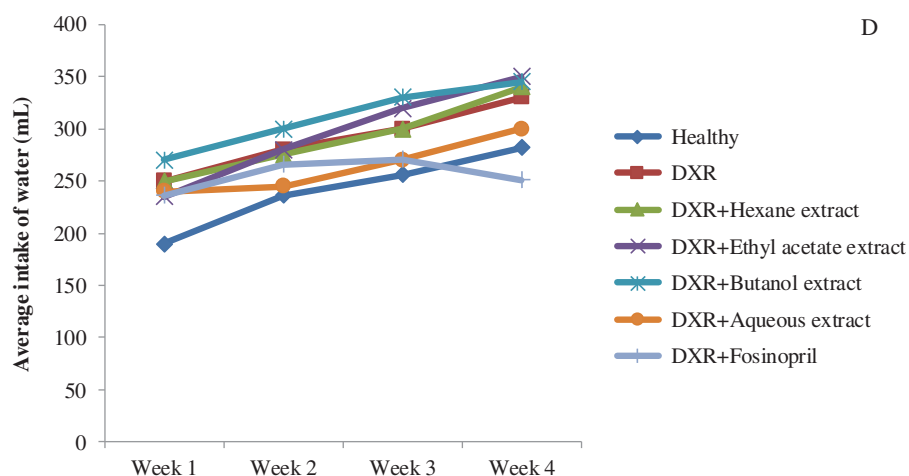


Figure 1. Continued.

Table 2. Effect of *Asparagus falcatus* on doxorubicin induced renal toxicity parameters.

Treatment	Serum urea nitrogen (mmol/L)	Serum creatinine (μ mol/L)	Serum total protein (g/dL)	Serum albumin (g/dL)	Urine Total Protein (g/dL)	Serum β_2 -microglobulin (μ g/mL)	Serum cystatin C (ng/mL)
Healthy control	0.44 \pm 0.01 [#]	57.10 \pm 1.74 [#]	6.46 \pm 0.32 [#]	3.01 \pm 0.14	57.51 \pm 13.38 [#]	3.80 \pm 0.22 [#]	21.54 \pm 1.42
DXR control	0.87 \pm 0.04 ^{*▲}	82.80 \pm 6.53 ^{*▲}	4.37 \pm 0.33 ^{*▲}	2.34 \pm 0.12	152.44 \pm 34.88 ^{*▲}	4.44 \pm 0.14 [*]	37.33 \pm 11.99 [▲]
DXR + Hexane extract	0.64 \pm 0.09 [#]	57.46 \pm 2.39 [#]	6.22 \pm 0.44 [#]	3.17 \pm 0.19 [#]	65.95 \pm 13.77 [#]	3.79 \pm 0.14 [#]	23.31 \pm 3.60
DXR + Ethyl acetate extract	0.60 \pm 0.08 [#]	61.25 \pm 3.32 [#]	6.15 \pm 0.35 [#]	3.24 \pm 0.22 [#]	61.18 \pm 7.81 [#]	3.65 \pm 0.04 [#]	23.43 \pm 1.54
DXR + Butanol extract	0.68 \pm 0.04 ^{*#}	62.14 \pm 4.60 [#]	5.89 \pm 0.27	2.76 \pm 0.13	39.31 \pm 8.59 [#]	3.53 \pm 0.02 [#]	27.45 \pm 1.65
DXR + Aqueous extract	0.50 \pm 0.02 [#]	60.21 \pm 1.65 [#]	6.14 \pm 0.30 [#]	2.98 \pm 0.15	47.13 \pm 3.13 [#]	3.54 \pm 0.04 [#]	23.69 \pm 2.74
DXR + Fosinopril (positive control)	0.58 \pm 0.03 [#]	57.46 \pm 2.16 [#]	6.04 \pm 0.31 [#]	2.85 \pm 0.29	72.08 \pm 2.89 [#]	3.94 \pm 0.18	16.59 \pm 0.63 [#]

DXR: doxorubicin. The treatment groups consisted of experimental rats administered with hexane, ethyl acetate, butanol, and aqueous extracts of *A. falcatus* respectively. Data values are represented in mean \pm SEM ($n = 6$).

^{*} $p < 0.05$ vs. normal healthy rats.

[#] $p < 0.05$ vs. doxorubicin control rats.

[▲] $p < 0.05$ vs. positive control rats.

Results

Effect of AF on body weight, food consumption, and water intake in doxorubicin-intoxicated rats

The normal control rats gained weight over 11 g/week during the study period of 28 days, while the experimental rats from the doxorubicin control group gained weight of nearly 6 g/week (Figure 1(A)). As shown in Figure 1(B), the 28-day treatment of hexane, ethyl acetate, and butanol extracts of AF resulted in a significant attenuation of the reduction in body weight gain with respect to the control rats ($p < 0.05$).

The average food consumption of the experimental animals (Figure 1(C)) varied in a pattern that corresponds with the changes in their body weight. However, no significant variation was observed in the water intake of the experimental rats throughout the study period of 28 days as illustrated in Figure 1(D).

Effect of AF on biochemical markers of renal function in doxorubicin-intoxicated rats

The induction of renal toxicity with doxorubicin in experimental rats caused marked renal toxicity in group DXR as evident from the results in Table 2. The treatment with hexane,

ethyl acetate, butanol, and aqueous extracts of AF markedly improved the renal functions of the doxorubicin intoxicated rats manifested by a significant reduction in serum creatinine, urea nitrogen, β_2 -microglobulin, and proteinuria, compared to the doxorubicin control rats ($p < 0.05$). A statistically significant positive correlation was observed in serum urea nitrogen ($r = 0.632$, $p = 0.003$), β_2 -microglobulin ($r = 0.564$, $p = 0.002$), cystatin C ($r = 0.496$, $p = 0.019$) and proteinuria ($r = 0.375$, $p = 0.000$) with serum creatinine. The nephroprotective activity deviated in the decreasing order of hot water > ethyl acetate > hexane > butanol extracts among the four selected extracts of AF with reference to the assessed biochemical parameters of renal function.

A significant decrease was observed in serum creatinine (31%), urea nitrogen (33%), cystatin C (56%), and proteinuria (53%) ($p < 0.05$) in the fosinopril treated rats with renal toxicity. Interestingly, all four AF extracts were more effective in reducing elevated levels of β_2 -microglobulin and total urine protein compared to the standard drug-fosinopril.

Effect of AF on antioxidant enzymes and lipid peroxidation in doxorubicin-intoxicated rats

Hexane, ethyl acetate, butanol, and aqueous extracts of AF were found to attenuate doxorubicin-induced oxidative stress

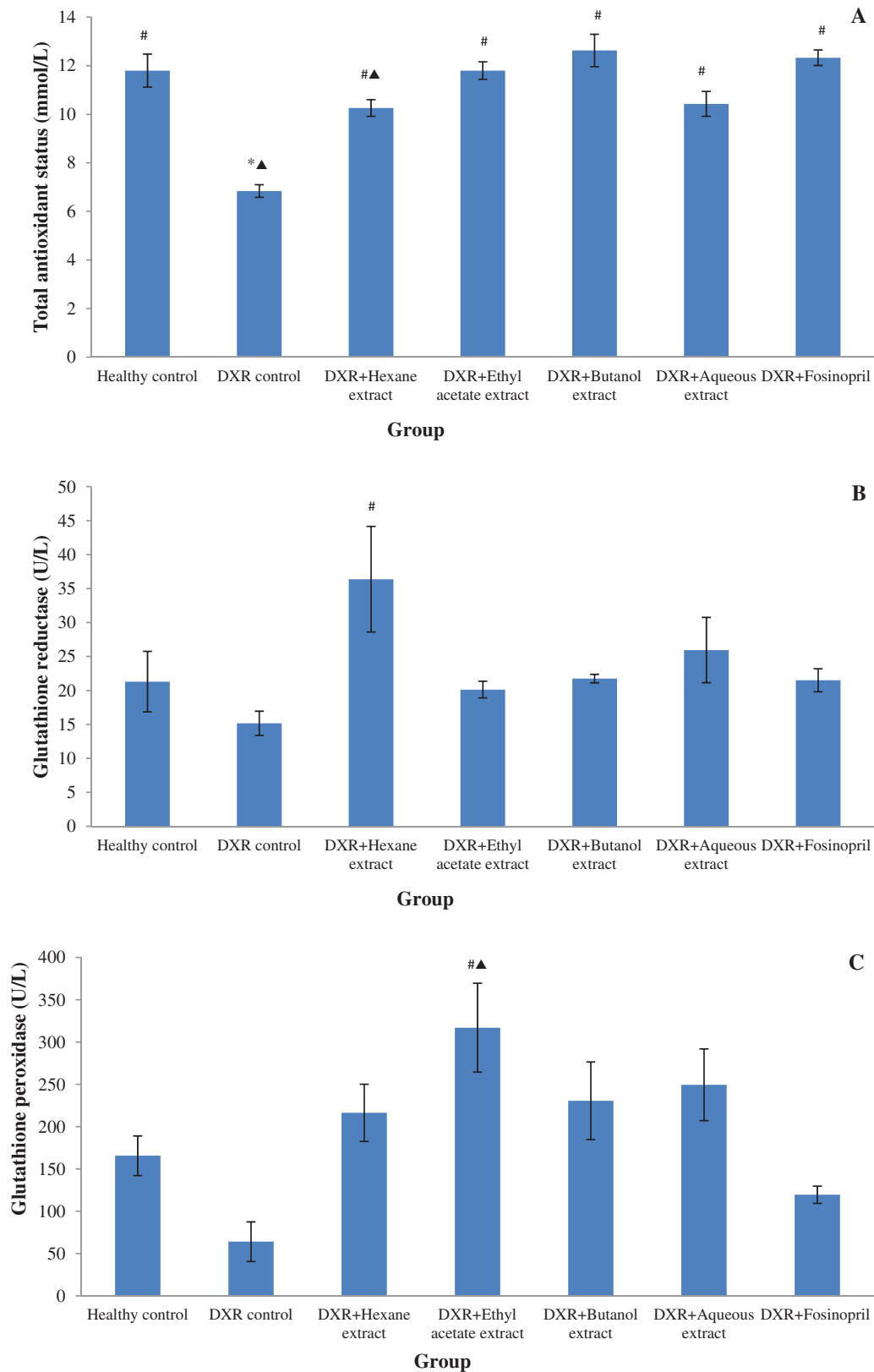


Figure 2. Effect of *Asparagus falcatus* on markers of oxidative stress; total antioxidant status (A), the activity of glutathione reductase (B), the activity of glutathione peroxidase (C), and lipid peroxidation (D) in doxorubicin-induced renal toxicity. DXR: doxorubicin. The treatment groups consisted of experimental rats administered with hexane (55 mg/kg), ethyl acetate (35 mg/kg), butanol (75 mg/kg), and aqueous (200 mg/kg) extracts of *A. falcatus* and the standard drug, fosinopril (0.09 mg/kg). Data values are represented in mean \pm SEM ($n=6$). The values are expressed in mean \pm SEM ($n=6$). * $p < 0.05$ vs. normal healthy rats, [#] $p < 0.05$ vs. doxorubicin control rats, [▲] $p < 0.05$ vs. positive control rats.

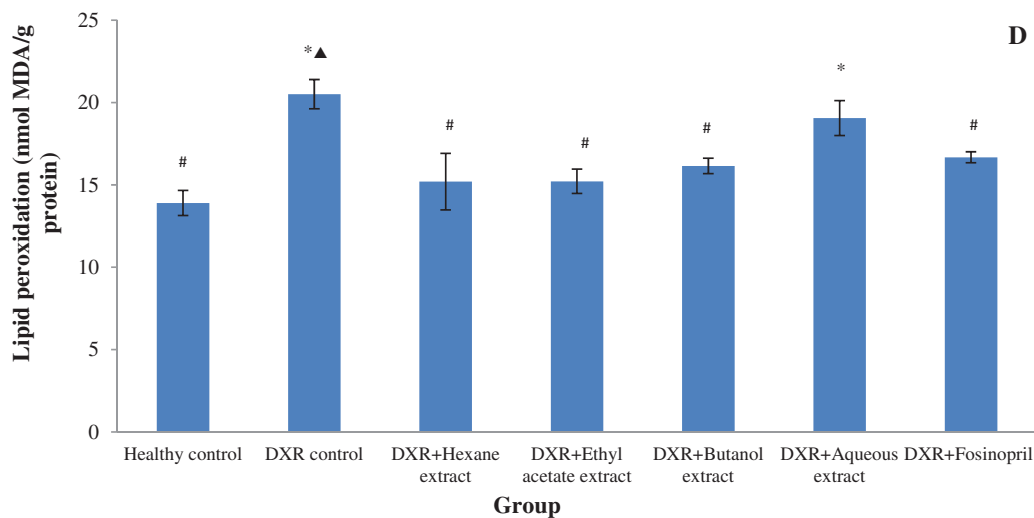


Figure 2. Continued.

by restoring antioxidant potential, as shown by increased values of total antioxidant status and activities of glutathione reductase and glutathione peroxidase (Figure 2). All four extracts of AF were found to be effective in increasing the total antioxidant status and the activity of glutathione peroxidase significantly compared to the doxorubicin control group ($p < 0.05$). However, a statistically significant increase in glutathione reductase and glutathione peroxidase activities was observed only with hexane and ethyl acetate extracts treated doxorubicin-intoxicated rats compared to doxorubicin control rats ($p < 0.05$). Yet, the selected extracts of AF showed relatively higher activity in the selected antioxidant enzyme levels compared to the standard drug- fosinopril.

Moreover, all the groups of experimental rats, except the rats treated with the aqueous extract (7%) showed a significant reduction in malondialdehyde formation in renal tissue homogenates compared to that in the doxorubicin control group ($p < 0.05$). Further, a statistically significant negative correlation and a positive correlation were observed respectively in total antioxidant status ($r = -0.519$, $p = 0.007$) and the lipid peroxidation ($r = 0.734$, $p = 0.000$) with serum creatinine concentrations of the experimental rats treated with the selected plant extracts.

Effect of AF on renal cytokines in doxorubicin-intoxicated rats

The effect of the selected extracts of AF on renal cytokines in the renal tissue homogenates is shown in Figure 3. Treatment with the selected extracts of AF for 28 consecutive days resulted in a suppression of the levels of both TNF- α (30%–54%) and IL-1 β (37%–52%) compared to that in the rats of the doxorubicin control group. The four AF extracts showed better suppression of IL-1 β compared to that of the standard drug, fosinopril ($p > 0.05$). There was a significant positive correlation ($r = 0.544$, $p = 0.005$) between the values of serum creatinine and TNF- α in experimental groups.

Effect of AF on immunohistochemical expression of COX-2, Bax, and BCL-2 in doxorubicin-intoxicated rats

The photomicrographs of the immunohistochemical expression of COX-2, Bax, and BCL-2 are shown in Figure 4(A–C) respectively. The degree of expression of COX-2, Bax, and BCL-2 by different groups of experimental rats, according to the semi-quantitative intensity scale are tabulated in Table 3. The doxorubicin control rats showed the highest expression of COX-2, as exhibited by intense brown staining, and the highest score, according to the semi-quantitative intensity scale (Figure 4(D)). The kidney sections from the normal healthy rats showed minimal immunostaining and the lowest score for COX-2. The treatment with the selected extracts of AF caused a reduction in COX-2 expression, compared to the doxorubicin control rats. Interestingly, the rats treated with butanol, and aqueous extracts showed a lower expression of COX-2, compared to the other two extracts of AF, as indicated by the findings on the semi-quantitative intensity scale.

The immunostaining of the pro-apoptotic protein, Bax, was comparatively high and mainly cytoplasmic in the experimental rats of the doxorubicin control group. The staining was visible mainly on the luminal surface of the proximal and distal tubular epithelial cells in the rats of the healthy control group and those of the treatment groups. Conversely, the expression of the anti-apoptotic protein BCL-2 in tubular epithelial cells was comparatively high in the normal healthy rats compared to that in the doxorubicin control rats. A uniformly positive cytoplasmic expression of BCL-2 was observed in the healthy control rats whereas, a focal positivity was observed in the doxorubicin control rats. The experimental rats treated with the selected extracts of AF showed enhanced immunostaining for BCL-2 compared to the doxorubicin control group. The findings on the apoptotic index of different groups of experimental rats are shown in Figure 4(E). The apoptotic index of the doxorubicin control group was significantly higher compared to those in the healthy control and the treatment groups by semi-quantitative analysis ($p < 0.05$). Interestingly, a significant reduction in the

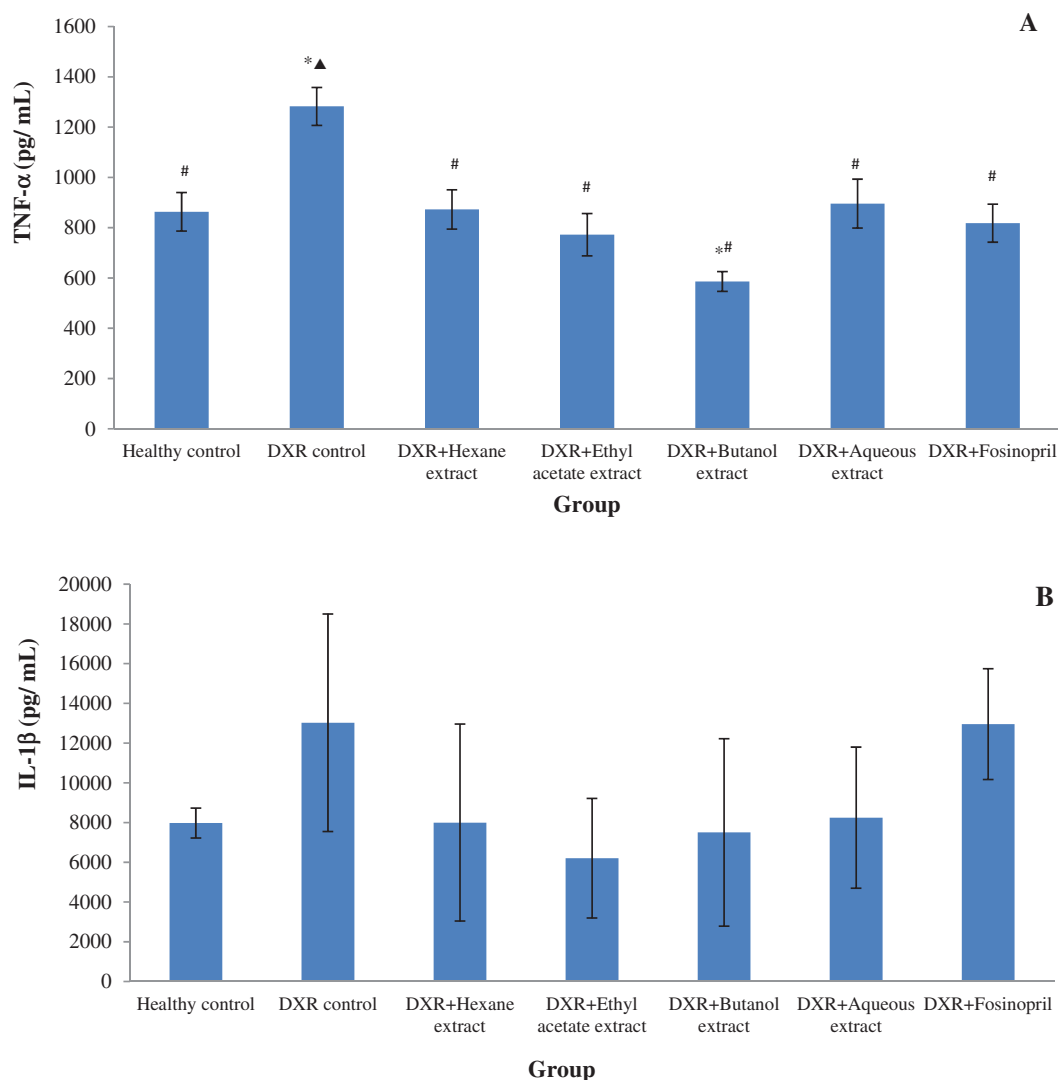


Figure 3. Effect of *Asparagus falcatus* on inflammatory cytokines; tumor necrosis factor- α (TNF- α) (A) and interleukin-1 β (IL-1 β) (B) in doxorubicin-induced renal toxicity. DXR: doxorubicin. The treatment groups consisted of experimental rats administered with hexane (55 mg/kg), ethyl acetate (35 mg/kg), butanol (75 mg/kg), and aqueous (200 mg/kg) extracts of *A. falcatus* and the standard drug, fosinopril (0.09 mg/kg). Data values are represented in mean \pm SEM ($n=6$). The values are expressed in mean \pm SEM ($n=6$). * $p < 0.05$ vs. normal healthy rats, # $p < 0.05$ vs. doxorubicin control rats, \blacktriangle $p < 0.05$ vs. positive control rats.

apoptotic index was observed in the group of rats treated with hexane, and aqueous extracts compared to the fosinopril administered group of rats ($p < 0.05$). Moreover, the values of apoptotic index and serum creatinine showed significant positive correlation in results ($r = 0.724$, $p = 0.001$).

Effect of AF on renal histological changes in doxorubicin-intoxicated rats

The administration of the selected extracts of AF for a period of 28 days attenuated doxorubicin-induced renal tubular and glomerular alterations as observed in the improved average histological scores of the experimental groups. Several significant improvements in the average total scores could be observed with the experimental rats treated with ethyl acetate (18%) and aqueous (22%) extracts of AF compared to the doxorubicin control rats. Interestingly, the histological sequence of nephroprotection as determined by the average histological scores of the four selected extracts was as same as the findings on biochemical markers of renal function,

further corroborating the superior nephroprotection by aqueous extract compared to the other three extracts of AF used in the present study. Pyknosis in the tubular epithelium, loss of brush border, and glomerular congestion were the most distinctive features observed in the doxorubicin control rats, in which the scores were reduced with the treatment of plant extracts. The photomicrographs of the H and E- stained renal sections are shown in Figure 5(B).

Discussion

Doxorubicin and its biologically reactive intermediates are reported to affect each intracellular compartment and metabolic event in the human body, including cell cycle, apoptosis, the metabolism of DNA, RNA, protein, lipids, etc. (Lahoti *et al.* 2012). Therefore, the elucidation of the potential mechanisms of nephroprotection by selected extracts of AF was carried out in terms of the evaluation of antioxidant, anti-inflammatory, and anti-apoptotic pathways in the present hypothesis.

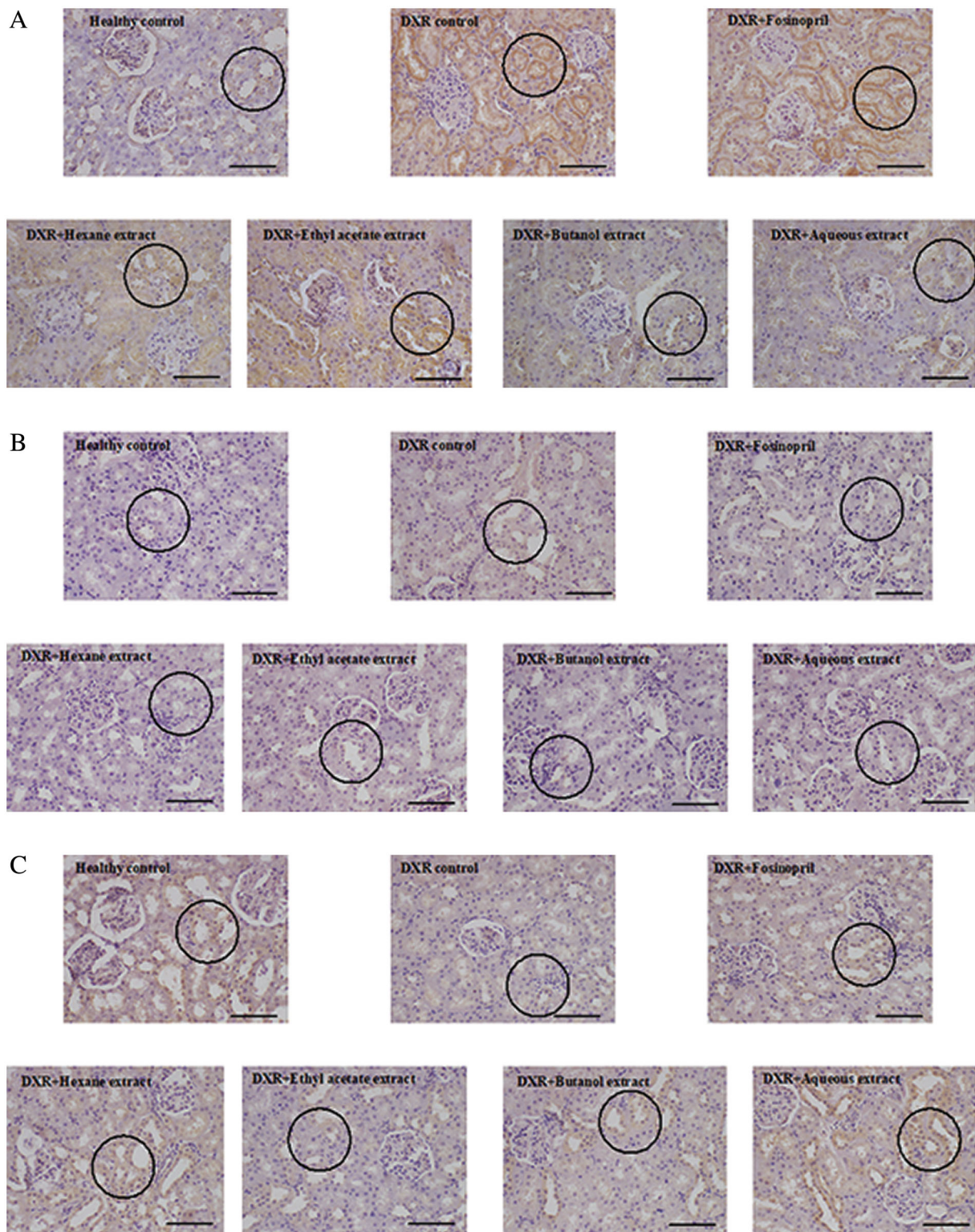


Figure 4. (A) Photomicrographs of immunohistochemical expression of COX-2 in renal sections (x400, Scale bar: 50 μ m). The highest expression of COX-2 is visualized by intense brown staining in the doxorubicin control rats. Minimal immunostaining for COX-2 is in the kidney sections of normal healthy rats. A reduction in COX-2 expression in treatment groups compared to the doxorubicin control rats signified potential anti-inflammatory effects. Reduced expression of COX-2 in kidney sections of the butanol and aqueous extract-treated group, compared to the other two extracts of *A. falcatus*. The tissue areas with positive COX-2 staining are circled in the photomicrographs. DXR: doxorubicin, COX-2: Cyclooxygenase 2. The treatment groups consisted of experimental rats administered with hexane (55 mg/kg), ethyl acetate (35 mg/kg), butanol (75 mg/kg), and aqueous (200 mg/kg) extracts of *A. falcatus* and the standard drug, fosinopril (0.09 mg/kg). (B). Photomicrographs of immunohistochemical expression of Bax in renal sections (x400, Scale bar: 50 μ m). Comparatively high immunostaining of the pro-apoptotic protein, Bax, in the cytoplasmic areas of the experimental rats of the doxorubicin control group. The staining is visible mainly on the luminal surface of the proximal and distal tubular epithelial cells, in the rats of the healthy control group and of the treatment groups. Reduced expression of Bax staining, in the experimental rats of the plant extracts treated groups signifying potent anti-apoptotic effects of *A. falcatus*. The tissue areas with positive Bax staining are circled in the photomicrographs. DXR: doxorubicin, Bax: B-cell associated X protein. The treatment groups consisted of experimental rats administered with hexane (55 mg/kg), ethyl acetate (35 mg/kg), butanol (75 mg/kg), and aqueous (200 mg/kg) extracts of *A. falcatus* and the standard drug, fosinopril (0.09 mg/kg).

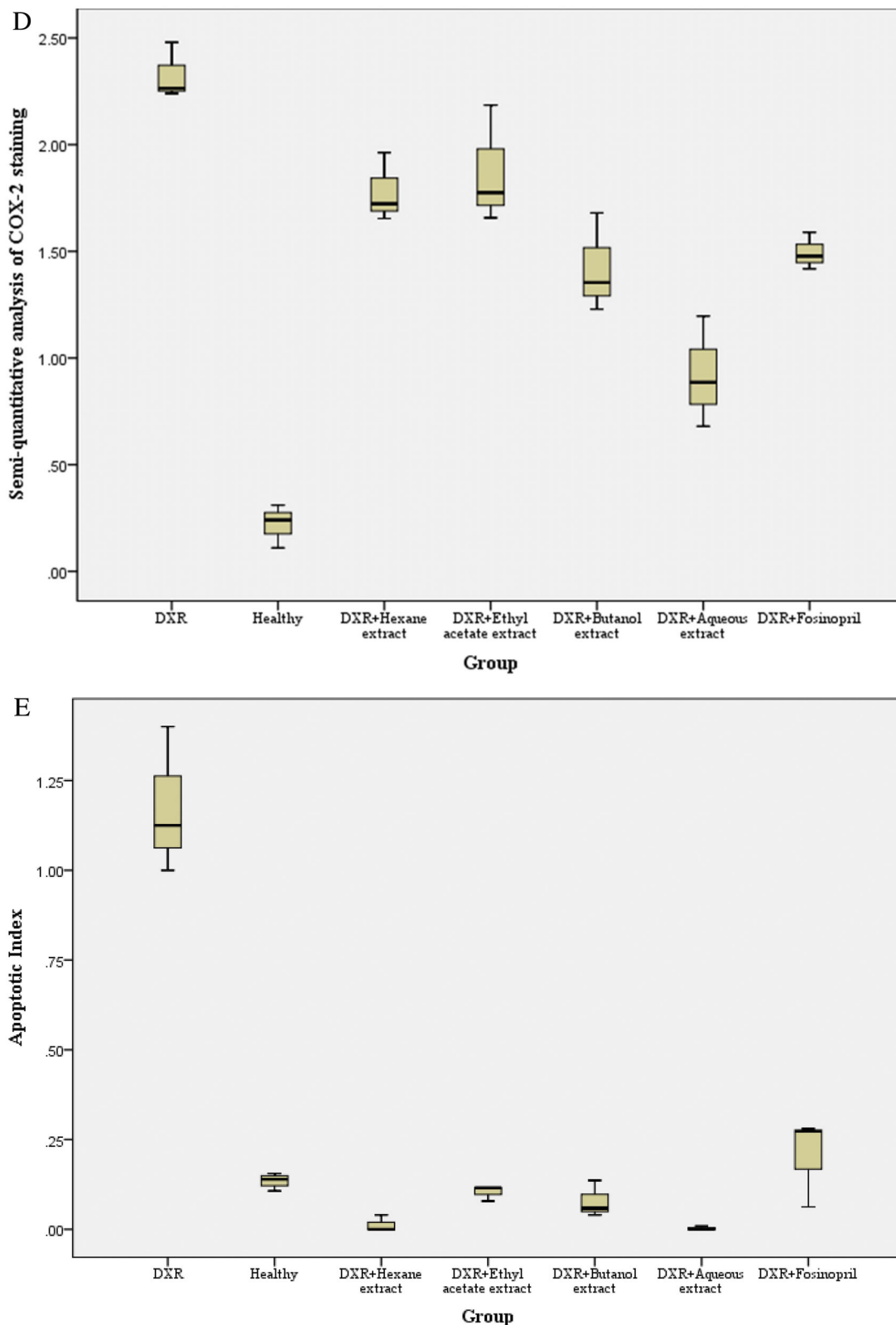


Figure 4. (C). Photomicrographs of immunohistochemical expression of BCL-2 in renal sections (x400, Scale bar: 50 μ m). The expression of the anti-apoptotic protein; BCL-2 in tubular epithelial cells was comparatively high in the normal healthy rats compared to the doxorubicin control rats. The presence of uniformly positive cytoplasmic expression of BCL-2 in the healthy control rats and the presence of focal positivity in the doxorubicin control rats. Enhanced immunostaining for BCL-2 in experimental rats treated with the selected extracts of *A. falcatus* compared to the doxorubicin control group signifying potential anti-apoptotic effects. The tissue areas with positive BCL-2 staining are circled in the photomicrographs. DXR: doxorubicin, BCL-2: B-cell lymphoma gene product 2. The treatment groups consisted of experimental rats administered with hexane (55 mg/kg), ethyl acetate (35 mg/kg), butanol (75 mg/kg), and aqueous (200 mg/kg) extracts of *A. falcatus* and the standard drug, foscipril (0.09 mg/kg). (D) Semi-quantitative analysis of COX-2 immunostaining in rats with doxorubicin-induced renal toxicity. DXR: doxorubicin, COX-2: Cyclooxygenase 2. The treatment groups consisted of experimental rats administered with hexane (55 mg/kg), ethyl acetate (35 mg/kg), butanol (75 mg/kg), and aqueous (200 mg/kg) extracts of *A. falcatus* and the standard drug, foscipril (0.09 mg/kg). (E) Effect of *Asparagus falcatus* on apoptotic index in rats with doxorubicin-induced renal toxicity. DXR: doxorubicin, apoptotic index: the ratio of percentage number of cells stained with Bax and percentage number of cells stained with BCL-2; Bax/BCL-2 ratio. The treatment groups consisted of experimental rats administered with hexane (55 mg/kg), ethyl acetate (35 mg/kg), butanol (75 mg/kg), and aqueous (200 mg/kg) extracts of *A. falcatus* and the standard drug, foscipril (0.09 mg/kg).

Table 3. Degree of immunohistochemical expression of COX-2, Bax, and BCL-2 in doxorubicin-induced renal toxicity based on the semi-quantitative intensity scale.

Treatment	COX-2	Bax	BCL-2
Healthy control	0.23 ± 0.03 [#]	0.19 ± 0.02	1.43 ± 0.03 [#]
DXR control	2.32 ± 0.06*	0.58 ± 0.07	0.50 ± 0.06*
DXR + Hexane extract	1.79 ± 0.18*	0.02 ± 0.02* [#]	1.47 ± 0.03 [#] ▲
DXR + Ethyl acetate extract	1.87 ± 0.15*	0.14 ± 0.01	1.33 ± 0.03
DXR + Butanol extract	1.43 ± 0.23 [#]	0.10 ± 0.01 [#]	1.27 ± 0.22
DXR + Aqueous extract	0.92 ± 0.17 [#]	0.01 ± 0.01* [#]	1.92 ± 0.21 [#] ▲
DXR + Fosinopril (positive control)	1.50 ± 0.08 [#]	0.11 ± 0.03	0.62 ± 0.09

DXR: doxorubicin.

The treatment groups consisted of experimental rats administered with hexane (55 mg/kg), ethyl acetate (35 mg/kg), butanol (75 mg/kg) and aqueous (200 mg/kg) extracts of *A. falcatus* and the standard drug, fosinopril (0.09 mg/kg). Data values are represented in mean ± SEM ($n = 6$).

* $p < 0.05$ vs. normal.

A single intraperitoneal dose of doxorubicin (5 mg/kg) was used to induce renal toxicity in experimental rats, based on the findings of preliminary experiments. The particular dose resulted in significant nephrotoxicity in experimental animals and did not cause mortality in rats during the 28-day long study period. Intraperitoneal administration was a convenient way of administering DXR to laboratory animals. In fact, the use of a single intraperitoneal dose of DXR to induce nephrotoxicity is supported by previous literature (Adikay 2016, Khan *et al.* 2020, Molehin 2020). The duration of treatment regimens was in accordance with the published reports on ameliorative therapies against doxorubicin-induced kidney injury (Mohan *et al.* 2010, Rajasekaran 2019). Further, the particular duration of treatment regimens simulates the long-term, low-level consumption of medicinal herbs practiced in traditional medicine.

The findings on biochemical parameters of renal function substantiate the renal injury induced by doxorubicin at the dose of 5 mg/kg, and the findings are further supported by previous literature (Szalay *et al.* 2015, Khajavi-Rad *et al.* 2017, Heravi *et al.* 2018). The morphological examination of kidney sections of the experimental rats revealed the features of acute tubular injury, further corroborating the findings on renal function parameters. It is known that acute tubular injury is often reversible, and a full recovery could be achieved by timely identification and proper management (Kumar *et al.* 2014). This was further confirmed by the present findings on the treatment groups which showed significant attenuation of the doxorubicin-induced acute tubular injury as reflected in the reduced average histological scores. Pyknosis and the loss of brush border in the tubular epithelium were the distinctive features observed in rats in the doxorubicin control group, and substantial attenuation of those two features was observed in the groups of rats treated with the plant extracts.

The findings on oxidative stress markers in renal tissue homogenates suggest potential antioxidant effects of the plant, as reflected by increased levels of antioxidant enzymes and suppression of lipid peroxidation, following treatment with the leaf extracts of AF. The ethyl acetate extract showed considerably higher glutathione peroxidase activity, which is significantly different from the standard drug. This could be

attributed to the presence of higher content of polyphenols and flavonoids in the ethyl acetate extract than in the other three extracts of AF (unpublished data, Jing *et al.* 2015). However, the present findings corroborate the findings of Earle *et al.* (2016) who reported that exogenous antioxidants from medicinal plants might restore antioxidant enzyme activity in renal toxic rats, reducing the oxidative damage caused by doxorubicin (Earle *et al.* 2016). Moreover, the hexane, ethyl acetate, and butanol extracts of AF attenuated lipid peroxidation in the renal tissue homogenates more effectively than the standard drug, further substantiating better antioxidant potential of the selected extracts compared to the standard drug, fosinopril. Different mechanisms of nephroprotection by the standard drug and the leaf extracts of AF could cause these substantial deviations in antioxidant potential *in vivo*. Reduction of hyperfiltration by the effect on glomerular perfusion is the mode of action by which the angiotensin-converting enzyme inhibitors decelerate the progression of kidney damage, whereas plant extracts exert their protective effects mainly via antioxidant effects (Jones and Tomson 2018). The potential antioxidant effect of AF is further corroborated by previously published findings by Hewawasam *et al.* (2008).

Recent literature state that the activation of tubular epithelial cells during the initiation phase of acute tubular injury results in the up-regulation of a variety of cytokines such as TNF- α and IL-1 β that contribute to the initiation of the inflammatory cascade (Basile *et al.* 2011). Induction of renal toxicity with doxorubicin resulted in a substantial increase in the concentrations of TNF- α and IL-1 β in the renal tissue homogenates of the experimental rats. These findings were further corroborated by increased immunohistochemical expression of the inducible enzyme; COX-2 in renal sections of doxorubicin control rats, which confirms the induction of inflammation by doxorubicin (Ibrahim *et al.* 2020). Doxorubicin provokes an array of inflammatory reactions in renal tissues by up-regulating NF- κ B level and stimulating the expression of subsequent pro-inflammatory mediators including TNF- α and IL-1 β (Khan *et al.* 2020). Furthermore, increased expression of IL-1 β activates COX-2, which is the main enzyme in prostanoid synthesis (Ibrahim *et al.* 2018, Safhi 2018). The treatment of doxorubicin intoxicated rats with the selected extracts of AF depleted the expression of the inflammatory markers compared to the doxorubicin control group. The four selected AF extracts demonstrated a better anti-inflammatory potential than the standard drug when considering the findings in a communal way. Furthermore, butanol extract showed a better anti-inflammatory potential compared to the other three extracts considering the concentrations of TNF- α and IL-1 β . Similar findings were also observed in the immunohistochemical expression of COX-2 as signified by the findings of the semi-quantitative analysis of COX-2 staining. All these findings support the compelling anti-inflammatory properties of AF against doxorubicin-induced renal toxicity.

The presence of the characteristics of acute tubular injury and the absence of inflammatory infiltration in renal sections of the experimental rats of the doxorubicin control group proposes the propagation of apoptotic cell death rather than

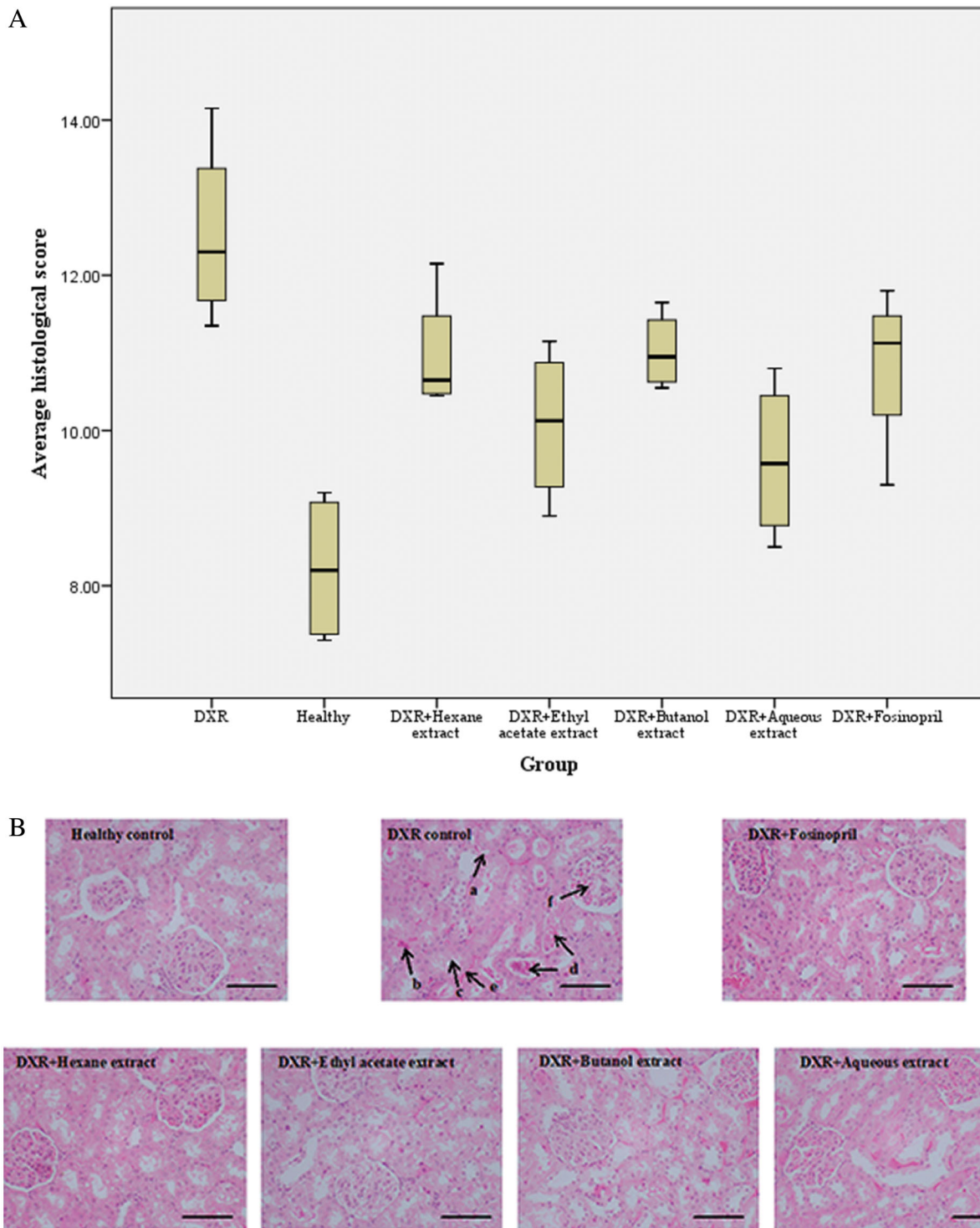


Figure 5. (A) Effect of *Asparagus falcatus* on the average total histological score of hematoxylin and eosin-stained renal tissues in rats with doxorubicin-induced renal toxicity. DXR: doxorubicin. The treatment groups consisted of experimental rats administered with hexane (55 mg/kg), ethyl acetate (35 mg/kg), butanol (75 mg/kg), and aqueous (200 mg/kg) extracts of *A. falcatus* and the standard drug, fosinopril (0.09 mg/kg). (B). Photomicrographs of hematoxylin and eosin-stained renal tissues of rats with doxorubicin-induced renal toxicity (x400, Scale bar: 50 μ m). The features of acute tubular injury as shown in DXR control are as follows; a: tubular cell vacuolization, b: pyknosis of tubular epithelial cells, c: loss of brush border in the tubular epithelium, d: cast formation, e: intertubular hemorrhage, and f: glomerular congestion. DXR: doxorubicin. The treatment groups consisted of experimental rats administered with hexane (55 mg/kg), ethyl acetate (35 mg/kg), butanol (75 mg/kg), and aqueous (200 mg/kg) extracts of *A. falcatus* and the standard drug, fosinopril (0.09 mg/kg).

necrotic cell death, which is the key event in doxorubicin-induced renal toxicity in the present study. The absence of the morphological features of interstitial fibrosis further substantiates the discontinuation of the inflammatory pathways that lead to necrosis. These findings are consistent with the possible explanation of Basile *et al.* (2011), who suggested

that most tubular epithelial cell death induced by renal toxic agents is secondary to apoptosis (Basile *et al.* 2011). The regulation of the intrinsic apoptotic pathway is mainly via a series of regulatory proteins, in which BCL-2 proteins including Bax and BCL-2 play a crucial role (Lahoti *et al.* 2012). Activation of the pro-apoptotic protein, Bax increases the

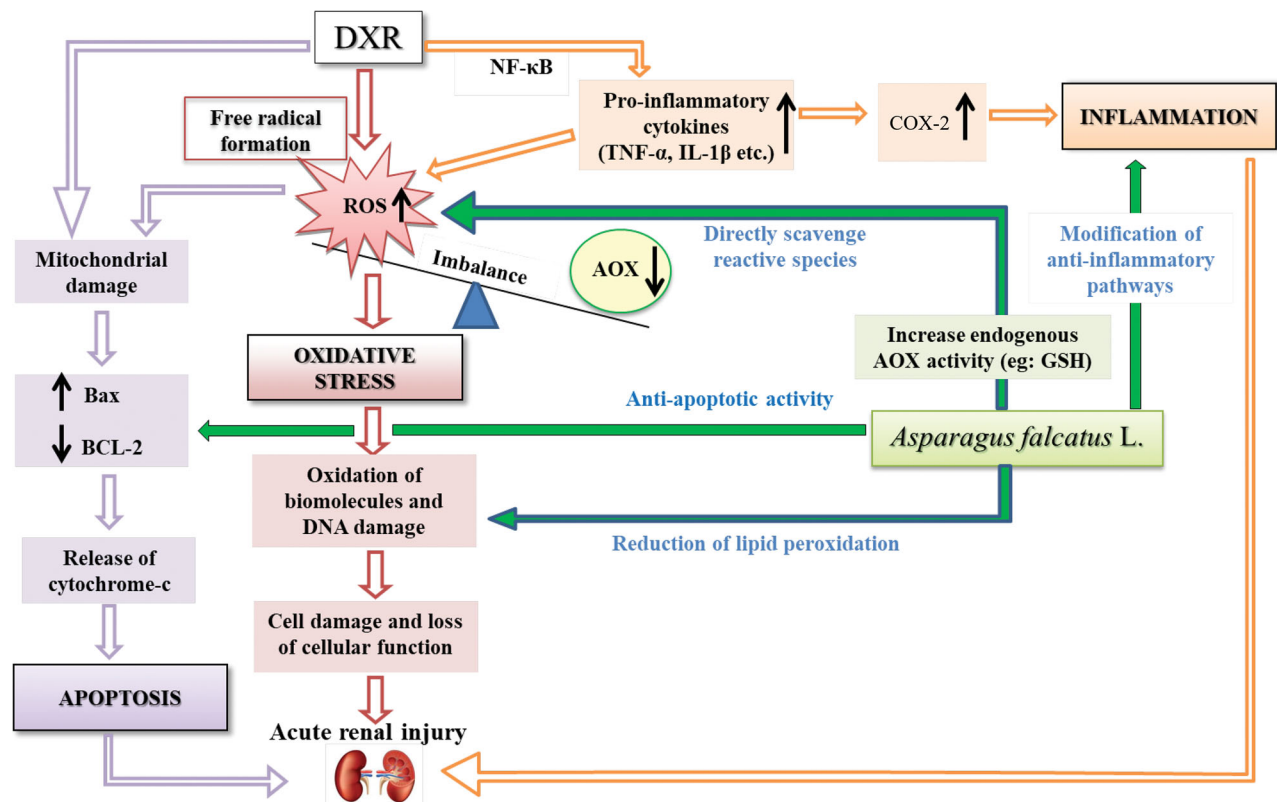


Figure 6. Schematic representation of potential mechanisms of nephroprotection by *Asparagus falcatus* L. DXR: doxorubicin, AOX: antioxidants, ROS: reactive oxygen species, NF- κ B: a transcription factor, TNF- α : tumor necrosis factor- α , IL-1 β : interleukin-1 beta, COX-2: cyclooxygenase 2, GSH: reduced glutathione, Bax: B-cell associated X protein, BCL-2: B-cell lymphoma gene product 2.

porosity of the mitochondrial membrane and augments the release of cytochrome-c from injured mitochondria initiating the intrinsic apoptotic pathway. On the contrary, the anti-apoptotic protein, BCL-2, located in the outer mitochondrial membrane, causes stabilization of mitochondrial integrity, avoiding translocation of cytochrome c into the outer cytosol (Lahoti *et al.* 2012, Ibrahim *et al.* 2020). Hence, the increased expression of Bax, the reduced expression of BCL-2 and significantly high apoptotic index resulted from semi-quantitative analysis of immunostained sections of the doxorubicin control group substantiate doxorubicin-induced apoptosis. The treatment with the selected extracts of AF opposed doxorubicin-induced apoptotic effects by decreasing the expression of Bax, increasing the expression of BCL-2, and attenuating the apoptotic index. These findings demonstrate promising anti-apoptotic properties of AF.

In fact, the significant negative correlation observed in total antioxidant status and the significant positive correlations observed in lipid peroxidation, TNF- α , and apoptotic index with the concentration of serum creatinine of the experimental rats treated with the selected extracts of AF, substantiate the fact that the nephroprotective effects of the plant could be attributed to the antioxidant, anti-inflammatory and anti-apoptotic effects *in vivo*. Figure 6 shows a schematic representation of the potential mechanisms of nephroprotection by AF, based on the findings in the present study.

The use of AF to attenuate doxorubicin-induced renal toxicity would be beneficial due to the anticancer effects

reported for the phytoconstituent eupalitin isolated from the plant (Ghalib *et al.* 2013). However, the therapeutic benefits of plant extracts of AF against doxorubicin-induced renal toxicity must be verified using exact animal models of cancer and subsequent clinical trials before commercializing a product as a supplement for patients on cancer chemotherapy.

Conclusions

This is the first *in vivo* study to elaborate on the nephroprotective mechanisms of AF in rats with renal toxicity. The outcomes of the present study revealed the potential attenuation of doxorubicin-induced renal injury by the hexane, ethyl acetate, butanol, and aqueous extracts of AF via suppression of doxorubicin mediated oxidative stress, inflammation, and apoptosis. The potential mechanisms of renal protection by the selected leaf extracts of AF could be due to the antioxidant, anti-inflammatory, and anti-apoptotic effects of its active metabolites. The aqueous extract exerted superior nephroprotective effects over the other extracts and the findings revealed the potency of the development of novel therapeutic drugs/nutraceuticals from AF to prevent doxorubicin-induced renal toxicity. In fact, AF could be recommended as a promising therapeutic agent to minimize renal toxicity induced by doxorubicin in cancer patients however, subsequent clinical trials are warranted.

Acknowledgement

The authors thank the technical staff of the Departments of Biochemistry and Pathology, Faculty of Medicine, University of Ruhuna, for providing technical support. Further, the authors would be grateful to Senior Professor Gamini Fonseka, Department of English & Linguistics, University of Ruhuna, Sri Lanka for providing the service of English language editing.

Disclosure statement

The authors report that there is no conflict of interest.

Funding

This work was supported by the Error! Hyperlink reference not valid. [RG/2016/HS-03] and the University Grants Commission special allocation to strengthen the research grant [RU/PG- R/16/14].

References

- Adikay, S., 2016. Phytoremedial effect of *Lens culinaris* against doxorubicin-induced nephrotoxicity in male Wistar rats. *International Journal of Green Pharmacy*, 10, 3.
- Ali, M., and Sultana, S., 2016. Phytochemical investigation of the aerial parts of *Protasparagus falcatus* (L.) Oberm. *Journal of Pharmacognosy and Phytochemistry*, 5 (5), 184–188.
- Amarasiri, S.S., et al., 2020a. Protective effects of three selected standardized medicinal plants used in Sri Lankan traditional medicine on adriamycin induced nephrotoxicity in Wistar rats. *Journal of Ethnopharmacology*, 259, 112933.
- Amarasiri, S.S., et al., 2020b. Acute and 28-day repeated-dose oral toxicity assessment of *Abelmoschus moschatus* Medik. in healthy Wistar rats. *Evidence-Based Complementary and Alternative Medicine*, 2020, 1–14..
- Anon, 1985. *Ayurveda Pharmacopoeia*. Colombo, Sri Lanka: Department of Ayurveda.
- Bartels, H., Böhmer, M., and Heierli, C., 1972. Serum creatinine determination without protein precipitation. *Clinica Chimica Acta*, 37, 193–197.
- Basile, D.P., Anderson, M.D., and Sutton, T.A., 2011. Pathophysiology of acute kidney injury. *Comprehensive Physiology*, 2 (2), 1303–1353.
- Benzer, F., et al., 2018. Chemoprotective effects of curcumin on doxorubicin-induced nephrotoxicity in Wistar rats: by modulating inflammatory cytokines, apoptosis, oxidative stress and oxidative DNA damage. *Archives of Physiology and Biochemistry*, 124 (5), 448–457.
- Carlberg, I., and Mannervik, B., 1985. Glutathione reductase. *Methods in Enzymology*, 113, 484–490.
- Dhawan, B. N., and Srimal, R. C., 1997. *Acute Toxicity and Gross Effects. Laboratory Manual for Pharmacological Evaluation of Natural Products*. India: United Nations Industrial Development Organization of Economic Co-operation Development.
- Ding, Y., et al., 2011. Study of histopathological and molecular changes of rat kidney under simulated weightlessness and resistance training protective effect. *PLoS One*, 6 (5), e20008.
- Earle, K.A., et al., 2016. Modulation of endogenous antioxidant defence and the progression of kidney disease in multi-heritage groups of patients with type 2 diabetes: Prospective evaluation of early nephropathy and its treatment (PREVENT). *Journal of Translational Medicine*, 14 (1), 1–7.
- El-Sheikh, A.A., et al., 2012. Effect of coenzyme-Q10 on doxorubicin-Induced nephrotoxicity in rats. *Advances in Pharmacological Sciences*, 2012, 981461.
- Ghalib, R.M., et al., 2012. A novel caryophyllene type sesquiterpene lactone from *Asparagus falcatus* (Linn.); structure elucidation and anti-angiogenic activity on HUVECs. *Eur J Med Chem*, 47 (1), 601–607.
- Ghalib, R.M., et al., 2013. Eupalitin from *Asparagus falcatus* (Linn.) has anticancer activity and induces activation of caspases 3/7 in human colorectal tumor cells. *Journal of Medicinal Plants Research*, 7 (20), 1401–1405.
- Gopalasatheeskumar, K., 2018. Significant role of soxhlet extraction process in phytochemical research. *Mintage Journal of Pharmaceutical and Medical Sciences*, 7 (1), 43–47.
- Halliwell, B., and Gutteridge, J. M. C., 2000. *Free Radicals in Biology and Medicine*. 3rd ed: Oxford, UK: Oxford Science Publications.
- Heravi, N.E., et al., 2018. Doxorubicin-induced renal inflammation in rats: protective role of *Plantago major*. *Avicenna Journal of Phytomedicine*, 8 (2), 179–187.
- Hewawasam, R.P., Jayatilaka, K.A.P.W., and Pathirana, C., 2008. Effect of *Asparagus falcatus* on acetaminophen toxicity in mice: a comparison of antioxidative effect with N-acetyl cysteine. *Journal of Dietary Supplements*, 5 (1), 1–19.
- Ibrahim, A., et al., 2018. Nephroprotective effects of benzyl isothiocyanate and resveratrol against cisplatin-induced oxidative stress and inflammation. *Frontiers in Pharmacology*, 9, 1268.
- Ibrahim, K.M., et al., 2020. Protection from doxorubicin-induced nephrotoxicity by clindamycin: novel antioxidant, anti-inflammatory and anti-apoptotic roles. *Naunyn-Schmiedeberg's Archives of Pharmacology*, 393 (4), 739–748.
- Jayaweera, D. M. A., 1982. *Medicinal Plants (Indigenous and Exotic) Used in Ceylon*. Sri Lanka: National Science Foundation in Sri Lanka.
- Jing, L., et al., 2015. Antioxidant potential, total phenolic and total flavonoid contents of *Rhododendron anthopogonoides* and its protective effect on hypoxia-induced injury in PC12 cells. *BMC Complementary and Alternative Medicine*, 15 (1), 1–12.
- Jones, M., and Tomson, C., 2018. Acute kidney injury and “nephrotoxins”: mind your language”. *Clinical Medicine (London, England)*, 18 (5), 384–386.
- Khajavi-Rad, A., Mohebbati, R., and Hosseinian, S., 2017. Drug-induced nephrotoxicity and medicinal plants. *Iranian Journal of Kidney Diseases*, 11 (3), 169–179.
- Khan, T.H., et al., 2020. Naringenin prevents doxorubicin-induced toxicity in kidney tissues by regulating the oxidative and inflammatory insult in Wistar rats. *Archives of Physiology and Biochemistry*, 126 (4), 300–307.
- Kumar, V., Abbas, A. K., and Aster, J. C., 2014. *Robbins Basic Pathology*, 9th ed. New Delhi, India: Elsevier Inc.
- Lahoti, T.S., et al., 2012. Doxorubicin-induced in vivo nephrotoxicity involves oxidative stress-mediated multiple pro- and anti-apoptotic signaling pathways. *Current Neurovascular Research*, 9 (4), 282–295.
- Mohan, M., et al., 2010. Protective effect of *Solanum torvum* on doxorubicin-induced nephrotoxicity in rats. *Food and Chemical Toxicology*, 48 (1), 436–440.
- Molehin, O.R., 2020. Alleviation of doxorubicin-induced nephrotoxicity by *Clerodendrum volubile* leaf extract in Wistar rats: a preliminary study. *Journal of Herbalmed Pharmacology*, 9 (2), 138–144.
- Muriel, P., et al., 2001. Kupffer cells inhibition prevents hepatic lipid peroxidation and damage induced by carbon tetrachloride. *Comparative Biochemistry and Physiology. Toxicology & Pharmacology: CBP*, 130 (2), 219–226.
- Negrette-Guzmán, M., 2019. Combinations of the antioxidants sulforaphane or curcumin and the conventional antineoplastics cisplatin or doxorubicin as prospects for anticancer chemotherapy. *European Journal of Pharmacology*, 859, 172513.
- Paglia, D.E., and Valentine, W.N., 1967. Studies on the quantitative and qualitative characterization of erythrocyte glutathione peroxidase. *The Journal of Laboratory and Clinical Medicine*, 70 (1), 158–169.
- Rajasekaran, M., 2019. Nephroprotective effect of *Costus pictus* extract against doxorubicin-induced toxicity on Wistar rat. *Bangladesh Journal of Pharmacology*, 14 (2), 93–100.
- Safhi, M.M., 2018. Nephroprotective effect of Zingerone against CCl₄-induced renal toxicity in Swiss albino mice: molecular mechanism. *Oxidative Medicine and Cellular Longevity*, 2018, 2474831.
- Sampson, E.J., et al., 1980. A coupled-enzyme equilibrium method for measuring urea in serum: optimization and evaluation of the AACC study group on urea candidate reference method. *Clinical Chemistry*, 26 (7), 816–826.

- Sharma, S.B., and Gupta, R., 2015. Drug development from natural resource: a systematic approach. *Mini Reviews in Medicinal Chemistry*, 15 (1), 52–57.
- Szalay, C.I., et al., 2015. Oxidative/nitrative stress and inflammation drive progression of doxorubicin-induced renal fibrosis in rats as revealed by comparing a normal and a fibrosis-resistant rat strain. *PLoS One*, 10 (6), e0127090.
- Watanabe, N., et al., 1986. Urinary protein as measured with a pyrogallol red-molybdate complex, manually and in a Hitachi 726 automated analyzer. *Clinical Chemistry*, 32 (8), 1551–1554.
- Yu, X., et al., 2017. Inhibition of COX-2/PGE2 cascade ameliorates cis-platin-induced mesangial cell apoptosis. *American Journal of Translational Research*, 9 (3), 1222–1229.